

TRIPLE RENAL ARTERIES OF THE LEFT KIDNEY WITH ABERRANT LEFT GONADAL ARTERY

Dr. Sreekanth Tallapaneni¹, DR. Chandramala², Shashank Kumar Srivastav³, Shaik Zakir Hussain³, Samia Azaz⁴.

Department of Anatomy, Shadan Institute of Medical Sciences, Teaching Hospital & Research Centre. Hyderabad.

ARTICLE INFO

Corresponding Author:

Dr. Sreekanth T, Associate Professor,
Department of Anatomy, Shadan
Institute of Medical Sciences,
Teaching Hospital & Research Centre.
Peerancheruvu Hyderabad.

Key words: (Accessory renal artery)
(Tortuous) (Left gonadal artery)
(segmental branches)

ABSTRACT

Objective:

The purpose of this case report is to bring into light about three renal arteries supplying the left kidney which is a rarity. The cranial and caudal accessory renal arteries were of aortic in origin and had significance lumen size. The cranial artery terminated into two segmental arteries. The caudal renal artery gave rise to the left gonadal artery and the point of emergence of it showed a deep kink.

Materials And Methods: A formalin – fixed elderly male cadaver along with Routine instruments including Scalpel, Blade, Surgical forceps, Anatomical Forceps, Dissector, Metallic Scale with Calibrations along with a pair of gloves were used. The anterior abdominal wall was dissected layer by layer. The reflection of the peritoneum was traced both horizontally and vertically. The visceral organs like liver, stomach & intestines were all studied in Situ and dissected out. The duodenum, pancreas and spleen were all dissected away from the abdominal cavity and the peritoneum was stripped to visualize the kidneys.

Result: Dissection of an elderly male cadaver revealed a left kidney supplied by triple renal arteries i.e., double accessory renal arteries along with its main renal artery. The first accessory renal artery arose from the lateral aspect of the abdominal aorta by the side of superior mesenteric artery. It had tortuous horizontal course and terminated into two segmental branches. The proximal branch had its portal of entry just above the hilum and the second branch entered the kidney at the upper part of the hilum. The second accessory renal artery arose from the anterior aspect of the aorta much below the main renal artery. It had a horizontal course towards the hilum of the kidney but showed a kink due to the emergence of the left gonadal artery. There was an alteration in the hilar anatomy due to these three arteries.

Conclusion: Knowledge of the renal vascular variations is indispensable in the exploration and treatment of renal trauma, renal vascular hypertension, renal embolization, angioplasty or vascular reconstruction for congenital and acquired lesions, surgery for abdominal aortic aneurysm and conservative or radical renal surgery. Anatomical knowledge of such vascular variations is essential for the radiologists, urologists while performing angiograms and renal transplantations.

©2013, IJMHS, All Right Reserved

INTRODUCTION

Renal arteries are a pair of lateral branches from abdominal aorta. Just below the origin of superior mesenteric artery (1). Normally each kidney receives one renal artery which divides into anterior and posterior branches these in turn divide into segmental arteries irrigating the different renal segments (2). Classically a single artery supplies the kidney and is called the main renal artery (3). However, accessory renal arteries can also exist. The normal renal arteries enter the kidney through its hilum where as the accessory renal arteries might enter

the renal artery through the hilum or through the surfaces or poles of the kidney. Among the renal vascular variations double renal arteries are frequently discovered irrigating the left kidney (4).

The gonadal arteries arise from the front of the aorta, usually 1-2 inches (2.5-5 cm) below the renal arteries. These arteries are small and variable in their origin. In the male, the arteries diverge from each other and pass laterally over the front of the psoas major muscle in a retroperitoneal position. Each artery crosses in front of the

corresponding ureter giving a branch to it. The right gonadal artery runs behind the terminal portion of the ileum, while the left gonadal artery passes behind the sigmoid colon. The artery skirts the pelvic brim, and crosses anterior to the distal end of external iliac artery to enter the internal inguinal ring (5). Then it accompanies the ductus deferens through the inguinal canal to the testis (6). The gonadal artery arising from the main or accessory renal artery is referred as aberrant gonadal artery (7).

EMBRYOLOGY

The embryological explanation of these variations has been presented and discussed by Keibel F and Mall FP in great detail [8]. In an 18 mm fetus, the developing mesonephros, metanephros, suprarenal glands and gonads are supplied by nine pairs of lateral mesonephric arteries arising from the dorsal aorta. Felix divided these arterial pairs into three groups as follows: the 1st and 2nd arteries as the cranial group, the 3rd to 5th arteries as the middle group and 6th to 9th arteries as the caudal group. The middle group gives rise to renal arteries. Persistence of more than one renal arteries of the middle group results as multiple renal arteries [8]. Accessory renal arteries are found frequently on the left side an occurrence is as high as 30-35% of cases, these arteries usually enter the upper or lower poles of the kidney [9].

MATERIALS AND METHODS:

A formalin – fixed elderly male cadaver along with Routine instruments including Scalpel, Blade, Surgical forceps, Anatomical Forceps, Dissector, Metallic Scale with Calibrations along with a pair of gloves were used. Kidneys are a pair of excretory organs lying over the posterior abdominal wall on either side of vertebral column retroperitoneally. The anterior abdominal wall was dissected layer by layer. The reflection of the peritoneum was traced both horizontally and vertically The visceral organs like liver, stomach & intestines were all studied in Situ and dissected out. The duodenum, pancreas and spleen were all dissected away from the abdominal cavity and the peritoneum was stripped to visualize the kidneys. The fat and the renal fascia from anterior surfaces of the left kidney were removed. At the hilum of the kidney the left renal vein was seen draining into the Inferior Vena Cava (IVC).

RESULT/OBSERVATION

Dissection of an elderly male cadaver revealed a left kidney supplied by triple renal arteries i.e., double (Cranial and caudal) accessory renal arteries along with its main renal artery. The main renal artery arose from the antero lateral aspect of the aorta about 1.8 cm below the origin of superior mesenteric artery. It coursed horizontally to reach the hilum of the kidney.(Fig-1) The cranial (first) accessory renal artery arose from the lateral aspect of the abdominal aorta by the side of superior mesenteric artery. It was tortuous having horizontal course and terminated into two segmental branches. Both the segmental branches were tortuous. The proximal branch had its portal of entry just above the hilum and the distal branch entered the kidney at the upper part of the hilum just anterior to the vein. (Fig1&2) The caudal (second) accessory renal artery arose from the anterior aspect of the aorta 3.8 cms below the origin of the superior mesenteric artery and about 3.2 cms above inferior mesenteric It was longer and had a horizontal course towards the hilum of the kidney but showed a kink due to the emergence of the left gonadal artery from its inferior surface (Fig-2) A large

renal vein is seen running horizontally towards the inferior vena cava lying just below the main renal artery. Small tributaries are seen along the hilar margin draining into the main renal vein. (Fig 1&2) There was an alteration in both the horizontal and vertical disposition of hilar structures. Instead of Vein, Artery, Pelvis, (VAP) the vertical disposition was Artery, Vein, Pelvis, Artery (AVPA). (Fig -3) the hilar anatomy due to the segmental branches of cranial, main and caudal accessory arteries. The renal pelvis was placed most posteriorly. The right kidney did not exhibit any variation.

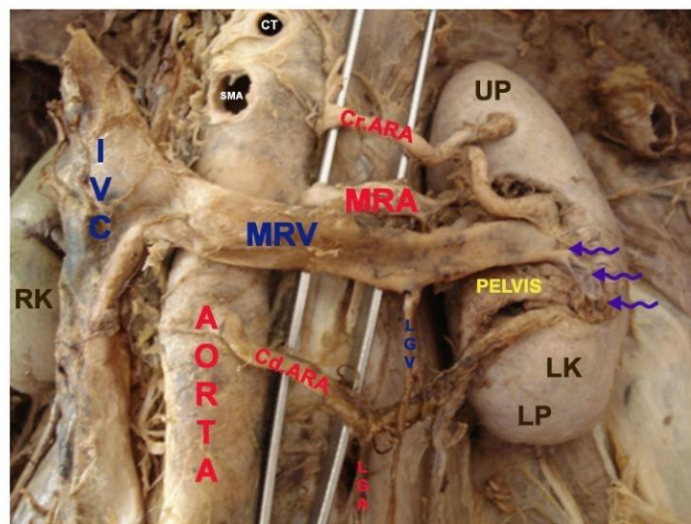


FIG - 1 ANTERIOR VIEW OF LEFT KIDNEY INSITU
 SMALL ARROW INDICATE THE SMALL CAPSULAR VEINS OPENING INTO THE LARGE MAIN RENAL VEIN. RK- RIGHT KIDNEY, LK -LEFT KIDNEY
 A-AORTA IMA-INFERIOR MESENTERIC ARTERY MRV-MAIN RENAL VEIN LGV-LEFT GONADAL VEIN LGA-LEFT GONAL ARTERY *KINKING OF CAUDAL ACCESSORY RENAL ARTERY MRA-MAIN RENAL ARTERY UP - UPPER POLE LP - LOWER POLE IVC INFERRIOR VENA CAVA
 CRARA- CRANIAL ACCESSORY RENAL ARTERY PR PROXIMAL BRANCH, DT DISTAL BRANCH
 CDARA-CAUDAL ACCESSORY RENAL ARTERY
 SMA-SUPERIOR MESENTERIC ARTERY
 CT COELIAC TRANK

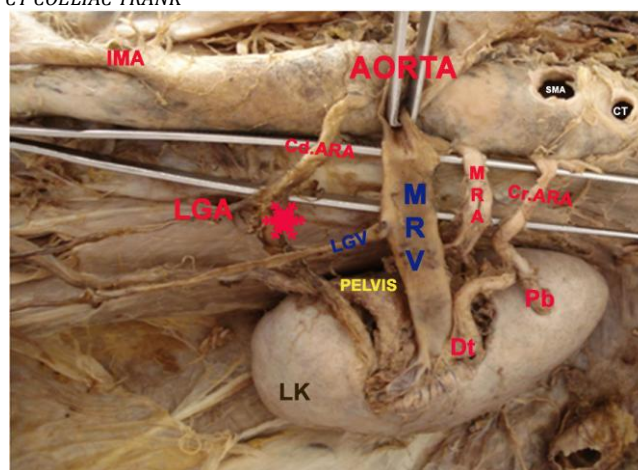


FIG - 2 SUPERIOR VIEW OF THE LEFT-KIDNEY INSITU
 A-AORTA IMA-INFERIOR MESENADAL VEIN MRV-MAIN RENAL VEIN LGV-LEFT GONADAL VEIN LGA-LEFT GONAL ARTERY *KINKING OF CAUDAL ACCESSORY RENAL ARTERY MRA-MAIN RENAL ARTERY
 CrARA- CRANIAL ACCESSORY RENAL ARTERY Pr PROXIMAL BRANCH, Dt DISTAL BRANCH
 CdARA-CAUDAL ACCESSORY RENAL ARTERY
 SMA-SUPERIOR MESENTERIC ARTERY
 CT COELIAC TRANK

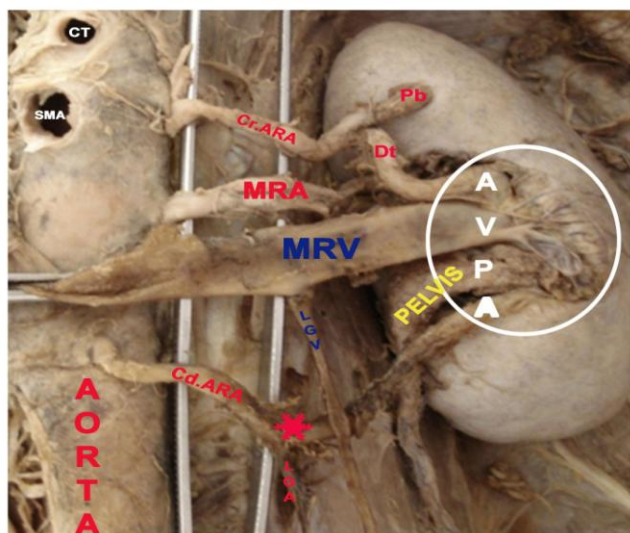


FIG-3 VERTICAL DISPOSITION OF THE HILAR STRUCTURES. (within the white ring) AVPA

A-AORTA MRV-MAIN RENAL VEIN LGV-LEFT GONADAL VEIN LGA-LEFT GONAL ARTERY

*-KINKING OF THE CAUDAL ACCESSORY RENAL ARTERY MRA-MAIN RENAL ARTERY

Cr.ARA- CRANIAL ACCESSORY RENAL ARTERY Pr PROXIMAL BRANCH, Dt DISTAL BRANCH

Cd.ARA-CAUDAL ACCESSORY RENAL ARTERY

SMA-SUPERIOR MESENTERIC ARTERY

CT COELIAC TRANK

DISCUSSION

K Khmanarong 2004 found single hilar artery in 82%, double in 17% (this includes 7% of upper polar arteries and 3% of lower polar arteries) & Three renal arteries in 1% (10). The statistical data signifies the rarity of the present case of a left kidney irrigated by triple renal arteries.

The incidence of triple renal arteries is reported to be 3.33% and the gonadal artery arising from renal artery was reported to be 10.0% by Ambica Wadhwa (11). The incidence of the left gonadal artery from the renal artery was reported by Cauldwell and Anson to be 4.3%, (12) by Pick and Anson to be 6.1%,(13) Notkovich to be 6.5% (14). In the present case the left gonadal artery arose from the caudal accessory renal artery.

Anupama Gupta 2011 states that presence of 5 to 6 pairs of renal arteries from dorsal aorta in frog, 3 pairs in domestic fowl and 3 or more in lizard is a normal phenomenon. Cranial pairs arise from abdominal aorta while the caudal ones from distal branches of aorta. 17 cadavers out of 60 showed the presence of accessory renal artery. In one of the cadavers three accessory renal arteries were seen on left side and two on right side. Our case shows presence of two accessory renal arteries on right side (15). In the present case the two accessory renal arteries arose directly from the aorta to supply the left kidney the cranial accessory had two terminal branches i.e., proximal and distal branch. The caudal accessory artery gave rise to the left gonadal artery

Dr. Neelesh Kanaskar reported double accessory renal arteries along with the main accessory artery irrigating the kidney the cranial artery gained its portal of entry by piercing the anterior substance of the kidney about 4 cm below the upper pole. The caudal accessory renal artery entered through the lower pole of the kidney (16). The present case had double accessory renal arteries supplying the left kidney. The cranial accessory artery terminated into a proximal and a distal branch the proximal branch had its portal of entry along the medial

border, just above the hilum about 2.2 cm below the upper pole. The caudal accessory renal artery had its portal of entry via the hilum just below and anterior to the renal pelvis.

S Bindu 2010 reported right accessory inferior polar renal artery coexisting with multiple vascular variations. Right Testicular artery was a branch of accessory renal artery. Right Obturator artery was a branch of posterior division of internal iliac artery (17). The present case is a vascular variation on the left side and the left gonadal artery arose from caudal accessory artery.

Llke Ali Gurses reports occurrence of double hilar renal arteries bilaterally. On right side, upper renal artery gave two suprarenal branches and lower renal artery gave a testicular branch in addition to a testicular artery that arose from aorta just proximal to inferior mesenteric artery. Superior left renal artery gave segmental branches and the lower renal artery gave testicular branch. (18) The present case report is a left sided unilateral variation where in the cranial accessory artery terminated into a proximal and distal branch. Both were supplying the left kidney. No branches arose to supply the supra renal glands. The caudal accessory renal artery gave rise to the left gonadal artery and the point of emergence showed a deep kink.

Bodei Petru studied 16 cases of gonadal arteries arising from the renal artery.. He reported in four cases of double renal arteries three of the gonadal arteries arose from the inferior accessory artery and in only one case the gonadal artery arose from superior accessory artery. He reported the origin of the gonadal artery from the inferior accessory artery in kidney supplied by triple renal arteries (19). In the present case report was similar to the case reported by him.

K S Satyapal studied 130 renal angiograms and 32 cadavers, reported the incidence of triple renal arteries is 4.5% occurring more commonly on left side accounting to 32% as compared to 23.3% on right side. In the present case the triple renal arteries were discovered only on the left side during the cadaveric dissection (20).

CONCLUSION

The incidence of triple renal arteries supplying a single kidney is a rare variation. The present case report is a rare combined variation of two accessory renal arteries and aberrant left gonadal artery. Both the accessory arteries were significantly large in size and the cranial artery had segmental branches. The caudal accessory renal artery had the gonadal artery arising from its inferior surface causing a kink at the point of its emergence. With the advent of laparoscopic renal procedures and donor nephrectomies it is essential for the surgeons to have thorough knowledge of these vascular variations. When the gonadal artery with renal origin is solitary without any second artery supplying that gonad then partial or total nephrectomies may lead to the compromise of the gonadal blood supply. A gonadal artery with origin from an accessory or inferior polar renal artery may be injured during the percutaneous treatment of the syndrome of pielo-ureteral junction, so it becomes a major contraindication.

REFERENCES

1. Patasi B, Boozary A. A case report: accessory right renal artery. *Int J Anal Var (IJAV)*.2009;2:119-121.

2. Gupta V, Kotgirwar S, Trivedi S, Deopujari R, Singh V. Bilateral variations in renal vasculature. *Int J Anat Var (IJAV)*. 2010;3:53-55.
3. Gurses IA, Kale A, Gayrelli O, Bayraktar B, Usta A, Kayaalp ME, AriZ, Bilateral variations of renal and testicular arteries. *Int J Anat Var (IJAV)*, 2009;2:45-47.
4. Bordei P, Sapte E, Iliesu D. Double renal arteries originating from the aorta. *Surg Radiol Anal* 2004; 26: 474-479.
5. Hollinshed WH. In: Great vessels and nerves of the abdomen, Vol. II. The thorax, abdomen and pelvis. *Anatomy for surgeons*. Paul B, Hoeber Inc, Medical book Department of Harper and Brothers, New York: 1956;594.
6. Romanes GJ. The blood vascular and lymphatic systems. In: *Cunninghams textbook of Anatomy*, 10th Ed. Oxford University Press, New York; Toronto: 1964;894-900.
7. Shoja MM, Tubbs RS, Shakeri AB, Oakes WJ. Origins of the gonadal artery: embryology implications. *Clin Anat*. 2007 May; 20(4):428-32.
8. Keibel F Mall FP (eds), *Manual of human embryology*, Vol. 2, J.B. Lippincott, Philadelphia, 1912, 820-825.
9. Singh G, NG YK, Bay BH, Bilateral accessory renal arteries associated with some anomalies of the ovarian arteries: a case study, *Clin Anat*, 1998, 11(6): 417-420.
10. Khamanarong K, Prachaney P, Utraravichien A, Tong-Un T, Shripaoraya Lx. Anatomy of Renal arterial supply. *Clinical anatomy* 2004; 17(4); 334-336.
11. Ambica Wadhwa, Sandeep Soni, A study of gonadal arteries in 30 adult human cadavers; *Clinical Medicine Insights: Reproductive Health*, 2010, 1-5.
12. Cauldwell EW, Anson BJ. The visceral branches of the abdominal aorta: Topographical relationships. *Am j Anat*. 1936; 73: 27-57.
13. Pick JW, Anson BJ. The inferior phrenic artery. Origin and suprarenal branches. *Anat Rec*. 1941; 81: 413-27.
14. Notkovich H. Variations off testicular and ovarian arteries in relation to the renal pedicle. *Surg Gynae Obst*. 1956; 103:487-95.
15. Anupama Gupta, Raman Gupta, Rajan Kumar Singhla. The Accessory Renal Arteries: A comparative Study in vertebrates with its Clinical Implications, *Journal of Clinical and Diagnostic Research* ; 2011, Vol 5(5), 970-973.
16. Neelesh Kanaskar, Vaishali Paranjape, Jyoti Kulkarni, Sapna Shevade,; Double Accessory Right Renal Arteries, *IOSR Journal of Dental and Medical Sciences (JDMS)* Volume 1, Issue 5, 2012, 17-20.
17. S. Bindhu, Aarathi Venunadhan, Zameera Banu, S Danesh, Multiple Vasccular Variations In A Single Cadaver: A Case Report, *Recent Research In Science And Technology* 2010, 2(5): 127-129.
18. Llike Ali Gurses, Aysin Kale, Ozean Gayretli, Bulen Bayraktar, Ahmet Usta, Mahmut Enes Kayaalp, Zafer ARI, Bilateral Variations Of Renal And Testicular Arteries, *International Journal Of Anatomical Variations*, 2009; 2; 45-47.
19. Bordei Petru, Sapte Elena, Iliescu Dan, Dina Constantin; The morphology and the surgical importance of the gonadal arteries originating from the renal artery. *Surg Radiol Anat*, 2007, 29: 367-371.
20. K S. Satyapal, A.A Haffejee, B. Singh, L. Ramsaroop, J.V.Robbssand, J.M. Kalideen. Additional Renal Arteries Incidence And Morphometry, *Surgical And Radiologic anatomy*, Vol 23, Number 1, 2001,33-38.